

See discussions, stats, and author profiles for this publication at: <https://www.researchgate.net/publication/321073223>

Visual snow syndrome: What we know so far

Article in *Current Opinion in Neurology* · November 2017

DOI: 10.1097/WCO.0000000000000523

CITATIONS

65

READS

22,534

4 authors, including:



Francesca Puledda

King's College London

54 PUBLICATIONS 890 CITATIONS

[SEE PROFILE](#)



Christoph Schankin

Inselspital, Universitätsspital Bern

155 PUBLICATIONS 6,860 CITATIONS

[SEE PROFILE](#)



Kathleen Digre

University of Utah

279 PUBLICATIONS 7,014 CITATIONS

[SEE PROFILE](#)

Some of the authors of this publication are also working on these related projects:



Moran CORE: Clinical Ophthalmology Resources for Education [View project](#)



Secondary Headache Special Interest Group of the International Headache Society [View project](#)



Visual snow syndrome: what we know so far

Francesca Puledda^a, Christoph Schankin^b, Kathleen Digre^c,
and Peter J. Goadsby^a

Purpose of review

We provide an overview of the neurological condition known as visual snow syndrome. Patients affected by this chronic disorder suffer with a pan-field visual disturbance described as tiny flickering dots, which resemble the static noise of an untuned television.

Recent findings

The term 'visual snow' has only appeared in the medical literature very recently. The clinical features of the syndrome have now been reasonably described and the pathophysiology has begun to be explored. This review focuses on what is currently known about visual snow.

Summary

Recent evidence suggests visual snow is a complex neurological syndrome characterized by debilitating visual symptoms. It is becoming better understood as it is systematically studied. Perhaps the most important unmet need for the condition is a sufficient understanding of it to generate and test hypotheses about treatment.

Keywords

palinopsia, persistent visual phenomena, photophobia, visual snow, visual static

INTRODUCTION

Since its first descriptions and clinical definition, visual snow is increasingly being recognized by physicians and researchers. The main clinical feature of the syndrome described consistently by patients is an unremitting, positive visual phenomena, present in the entire visual field and characterized by uncountable tiny flickering dots interposed between the person's vision and the background [1^{••}]. This 'static' is typically black and white but can also be colored, flashing, or transparent. In addition to the static, or snow, patients can experience additional visual symptoms of either direct neurological origin, such as palinopsia, photophobia, and nyctalopia (i.e., impaired night vision), or that arise from the optic apparatus. This is the case of entoptic phenomena, a set of different symptoms commonly found in visual snow syndrome [2], which may manifest as blue field entoptic phenomenon, floaters, self-light of the eye, spontaneous photopsia, or a combination of those.

The objective of this review is to highlight the available literature on visual snow to set out what is known of the clinical picture, pathophysiology, and available treatments for this hitherto largely unrecognized and disabling condition.

We performed a systematic literature search on PubMed for any relevant reports and articles on

visual snow up to July 2017; key words were 'visual snow', 'visual static', and 'persistent positive visual phenomena'.

In the first part we will present a summary of early literature reports on visual snow (also shown in Table 1), which mostly represent isolated clinical descriptions in the context of larger patient groups affected by persistent visual disturbance attributed to migraine aura. These reports are an example of how commonly visual snow can be misdiagnosed as a form of persistent visual aura, which seems to share some pathophysiological mechanisms with the syndrome, even though it clearly represents a separate disease entity [13].

We will then describe the main findings from the important studies that have represented the

^aHeadache Group, Department of Basic and Clinical Neuroscience, NIHR-Wellcome Trust King's Clinical Research Facility, King's College Hospital, King's College London, London, UK, ^bDepartment of Neurology, Bern University Hospital, University of Bern, Bern, Switzerland and ^cDepartments of Neurology, Ophthalmology, University of Utah, Salt Lake City, Utah, USA

Correspondence to Peter J. Goadsby, MD, PhD, Wellcome Foundation Building, King's College Hospital, London SE5 9PJ, UK. Tel: +44 203 299 3106; e-mail: peter.goadsby@kcl.ac.uk

Curr Opin Neurol 2018, 31:52–58

DOI:10.1097/WCO.0000000000000523

KEY POINTS

- Visual snow is a neurological condition characterized by the presence of a constant pan-field visual disturbance described as tiny flickering dots that resemble the noise of a detuned analogue television.
- In addition to visual static, patients are affected by disabling visual symptoms of the type of palinopsia (afterimages and trailing), entoptic phenomena (floaters, blue field entoptic phenomenon, photopsia, self-flight of the eye), photophobia, and nyctalopia forming visual snow syndrome.
- At the moment, very little is known about the pathophysiology of visual snow, as well as possible treatment strategies for affected patients. Further studies are necessary to improve our understanding of this distressing condition.
- The review encompasses the published literature on visual snow, systematically summarizing the key elements that characterize the phenotype of the syndrome, as well as what is known so far about its underlying mechanisms, clinical presentation, and possible directions for future research on this condition.

initial characterization and definition of the visual snow syndrome, finally moving onto a detailed description of the clinical phenotype and main pathophysiological hypotheses.

THE VISUAL SNOW SYNDROME

Early reports of visual snow

Our reading is that the first clear case report of visual snow in the literature was by Liu *et al.* [3]. In this study

10 migraine patients with positive persistent visual disturbance were grouped in three categories, defined by the authors on the basis of the relation between the headache condition and the visual symptoms. Astutely, three patients, with what can now clearly be identified as visual snow, were categorized in the study as study participants for which visual problems were not necessarily linked with migraine. The authors noted that even if there was a positive history for both clinical conditions, there was in fact no temporal or causal association between the two. It is interesting to note the personal description of one study participants symptoms, as ‘snow and flickering similar to what was between television (TV) channels’. About 10 years later, Jager *et al.* [4] was the first to use the term ‘visual snow phenomenon’ in the medical literature, describing a possible phenotypic variant of aura in a study using magnetic resonance perfusion and diffusion imaging on four patients with long lasting visual disturbances. Two patients were defined as having visual snow, and one described her disturbance as ‘thousands of small yellow, white, or silvery dots over the whole of both visual fields.’ In 2008 Wang *et al.* [5] used the Visual Aura Rating Scale to assess patients with persistent visual disturbance, and described two study participants with continuous TV static and noise in their vision or, to use the patient’s words, ‘tiny black and white dots scattered throughout the entire visual field.’

The first characterization of visual snow as a distinct phenomenon was a report in 2013 by Simpson *et al.* [7[■]]. The authors describe the case of a pediatric patient affected by migrainous headaches since age 7. The patient presented the sudden onset of a persistent visual disturbance described as ‘white bright jagged spots and black and white flashes with

Table 1. Studies on visual snow currently published in the literature

Authors	Year	Name given	Patient number	Procedure or treatment
Liu <i>et al.</i> [3]	1995	Persistent positive visual phenomena	<i>n</i> = 3	Case description
Jager <i>et al.</i> [4]	2005	Primary persistent visual disturbance/ visual snow phenomenon	<i>n</i> = 2	Diffusion and perfusion MRI
Wang <i>et al.</i> [5] and Chen <i>et al.</i> [6]	2008	Persistent visual aura without infarction	<i>n</i> = 2	Case description, visual aura rating scale, magnetoencephalography
Simpson <i>et al.</i> [7 [■]]	2013	Positive persistent visual symptoms/visual snow	<i>n</i> = 1	Case description
Schankin <i>et al.</i> [1 [■]]	2014	‘Visual snow’	<i>n</i> = 78	Semistructured telephone interview
Schankin <i>et al.</i> [8 [■]]	2014	‘Visual snow’	<i>n</i> = 17	[¹⁸ F]-FDG PET
Bessero <i>et al.</i> [9]	2014	‘Visual snow’	<i>n</i> = 20	Case description
Unal-Cevik and Yildiz [10]	2015	Visual snow	<i>n</i> = 1	Case description, MRI, VEPs, Lamotrigine treatment
Lauschke <i>et al.</i> [11]	2016	Visual snow	<i>n</i> = 32	Case description
McKendrick [12]	2017	Visual snow	<i>n</i> = 16	Visual performance tasks

FDG, fludeoxyglucose; VEP, visual evoked potentials.

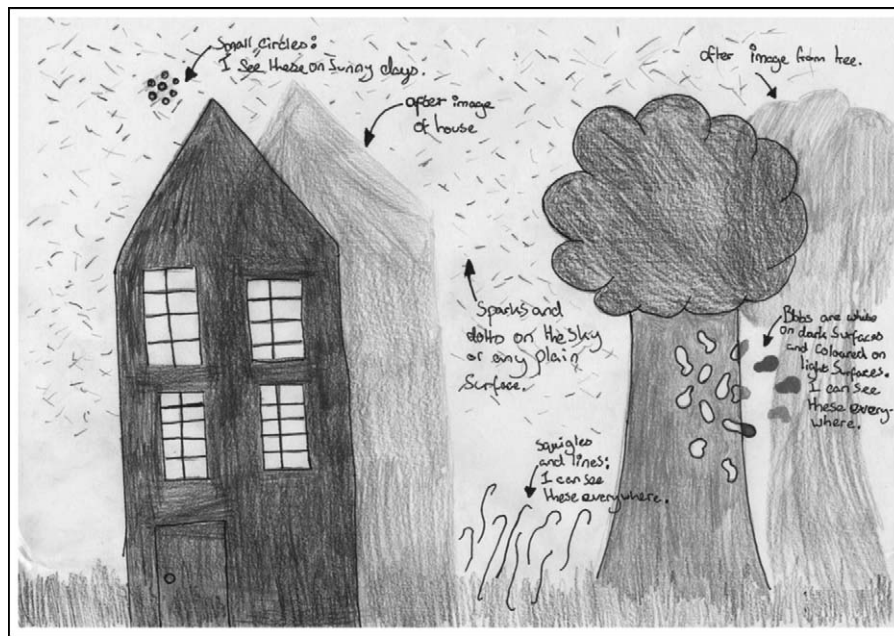


FIGURE 1. An original drawing of visual snow made by a 12-year-old patient, clearly showing the visual disturbances of snow, afterimages (palinopsia), and blue field entoptic phenomena. Reproduced with permission [7*].

sparkles and dots' 3 years later. The patient also reported other key additional symptoms of visual snow, such as palinopsia and photophobia (see Fig. 1).

Systematic characterization of the syndrome

These case reports or series, even if isolated and collected over decades, all described patients complaining of a reasonably homogeneous set of symptoms suggesting a unique common syndrome. The first systematic characterization of patients with visual snow used a three-step approach [1**]. At first, a preliminary set of criteria was proposed based on the reports of 22 patients seen by one of the authors (P.J.G.), as well as an internet survey completed by patients with self-assessed visual snow. These criteria were prospectively tested in 78 patients who all had visual snow, defined as 'dynamic, continuous, tiny dots in the entire visual field lasting longer than 3 months.' About 72 patients (92%) had at least three additional visual symptoms, supporting the hypothesis of a clinical syndrome ('visual snow syndrome') and resulting in the proposition of definitive clinical criteria (Table 2). About one-fourth of the interviewed patients had symptoms for as long as they could remember. In the remaining three-fourths, symptom onset was around age 20 and caused an important impact on quality of life. Most patients had comorbid migraine and many had typical migraine aura (27%) suggesting an

overlap of disease mechanisms. However, the study underlined how one of the substantial causes of distress for patients was the continuing and unremitting symptomatology of visual snow, which clearly lacks the episodic nature characteristic of migraine. Moreover, only a minority of study participants in the study had visual aura during the onset of visual snow syndrome, suggesting that visual snow is different from persistent migraine aura [1**]. The relation between migraine [9], typical migraine aura, and visual snow syndrome was further studied in 120 patients [8**]. Patients with visual snow syndrome and concomitant migraine as a comorbid condition were found to have more additional symptoms, in particular photophobia, palinopsia, photopsia, nyctalopia, and tinnitus. In contrast, such association was not found for comorbid migraine aura, which does not alter the typical phenotype of the visual snow syndrome. These results seem to suggest that migraine can aggravate the clinical presentation of the visual snow syndrome.

Pathophysiological hypotheses

The neurophysiological mechanisms causing visual snow syndrome are currently unknown. Based on its clinical description, however, some hypothesis can be proposed. It is unlikely for a whole-field visual disturbance to be caused by a disorder of the anterior retinogeniculate visual pathway, optic radiation, or

Table 2. Criteria for the definition of the visual snow syndrome

A	Visual snow: dynamic, continuous, tiny dots in the entire visual field lasting longer than 3 months The dots are usually black/grey on white background and grey/white on black background; however they can also be transparent, white flashing or colored
B	Presence of at least two additional visual symptoms of the four following categories: (i) Palinopsia. At least one of the following: afterimages or trailing of moving objects. After images should be different from retinal afterimages, which occur only when staring at a high contrast image and are in complementary color (ii) Enhanced entoptic phenomena. At least one of the following: excessive floaters in both eyes, excessive blue field entoptic phenomenon, self-light of the eye, or spontaneous photopsia. Entoptic phenomena arise from the structure of the visual system itself. The blue field entoptic phenomenon is described as uncountable little grey/white/black dots or rings shooting over visual field in both eyes when looking at homogeneous bright surfaces, such as the blue sky; self-light of the eye is described as colored waves or clouds when closing the eyes in the dark; spontaneous photopsia is characterized by bright flashes of light (iii) Photophobia (iv) Nyctalopia
C	Symptoms are not consistent with typical migraine visual aura As defined by the International Headache Society in the International Classification of Headache Disorders [14]
D	Symptoms are not better explained by another disorder Normal ophthalmology tests (best corrected visual acuity, dilated fundus examination, visual field, and electroretinogram); not caused by previous intake of psychotropic drugs

primary visual cortex, which are organized in a monocular or homonymous fashion; so a simple disorder of the visual pathway seems less likely. The additional phenotype of visual snow syndrome involves palinopsia, that is, the inability to suppress the just-seen [15] as well as enhanced entoptic phenomena, that is, the inability to suppress the visualization of the optic apparatus [16]. Visual snow syndrome therefore seems to involve the processing of visual information in the supplementary visual cortex, downstream of the primary visual cortex. This view is supported by the reports of normal eye examinations and visual evoked potentials (VEP) in visual snow patients [1[■]], as well as the results from the only functional brain imaging study performed on visual snow [8[■]]. In this study, involving 17 patients with visual snow syndrome who underwent [¹⁸F]-Fludeoxyglucose PET, hypermetabolism of the lingual gyrus was demonstrated. This area is part of the supplementary visual cortex and corresponds to Brodmann area 19. The pathophysiology of visual snow syndrome might therefore involve dysfunctional visual processing in the lingual gyrus, a theory also supported by studies on photophobia, a hallmark symptom of both visual snow syndrome [1[■]] and migraine [14]. Imaging data in fact suggest that the lingual gyrus is involved in the perception of photophobia during migraine [17] and furthermore shows larger cortical thickness in migraineurs when compared with patients without interictal photophobia [18]. This shared pathophysiology might thus in part explain the comorbidity of migraine and visual snow. Further, Brodmann area 19 differs from other cortical areas with regards to its

microstructure [19]; area 19 extends from the lingual gyrus to other brain areas including V3A, which is also the region identified as being the earliest to exhibit functional changes during migraine aura [20]. This suggests involvement of this structure in the generation of typical migraine aura and might be important for the shared pathophysiology of typical migraine aura and visual snow syndrome.

The question of visual cortical hyperexcitability in the pathophysiology of visual snow has been addressed by Chen *et al.* [6], who studied six patients with persistent visual disturbance using visual-evoked magnetic field recording. Two patients had reported what seemed to be visual snow for many years, and were found to have a persistent cortical hyperexcitability, which was inversely correlated with disease duration. This suggests that cortical excitability might differ between patients with visual snow and those with persistent visual disturbance of other origin, as is probably also reflected by the different pharmacological treatment options [21]. In a case report, Unal-Chevik and Yildiz [10] similarly found a potentiation of repetitive VEP in a patient with visual snow and migraine; this alteration normalized after treatment with lamotrigine in parallel to a clinical improvement. Whether the lack of habituation in these studies was because of comorbid migraine [22] or is also a characteristic of visual snow remains an open question.

In summary, the pathophysiology of visual snow is unclear, and further studies using strict criteria and control study participants matched for migraine and typical migraine aura are necessary to

improve our understanding of this distressing condition. The lack of knowledge on the basic biology of the syndrome leads to the absence of substantially effective treatment strategies. No clinical and systematic trials have been performed to date, and all available data on treatment of visual snow come from single patients or case reports. The current evidence seems to show that commonly used medications such as migraine preventives, antidepressants, or pain medication do not consistently improve or worsen visual snow [1²²,23]. There has been a single positive experience with lamotrigine [10] and one with naproxen [8²²], which however need be contemplated within their level of evidence.

Differential diagnosis and focus on associated symptoms

It is important for researchers and clinicians to distinguish visual snow from other phenomena and to recognize visual symptoms that can accompany visual snow syndrome. Here we focus on the associated visual symptoms in visual snow, to facilitate its differential diagnosis with other visual disorders.

When queried [1²²], about three-quarters of individuals with visual snow reported at least three of four accompanying visual phenomena, of the type of palinopsia, exaggerated entoptic phenomena, photophobia, and nyctalopia. These ancillary visual symptoms were so common in visual snow study participants that 97% reported more than one additional symptom and 92% reported up to three.

Palinopsia, also described as the persistence or continuation of an image after the stimulus is gone [15], is different from a retinal afterimage, a phenomenon that can commonly be experienced by healthy individuals [24]. Palinoptic images in visual snow can manifest as preserved images from stationary scenes in over 80% of individuals or as visual trailing in up to 60% of study participants [1²²,2]. Aside from constituting an important manifestation of the visual snow syndrome, palinopsia can be seen in neurological diseases with focal lesions [25], as a side-effect of commonly used preventive headache medications (e.g., topiramate and acetazolamide) [26,27], or as a visual phenomenon in migraine [28,29].

An exaggerated entopic phenomenon was reported in 81% of individuals with visual snow. Entoptic phenomena can be perceived quite commonly in the general population, however, the difference with visual snow patients is that they perceive them on a daily basis and in a bothersome, debilitating manner. The eye itself can have reflective powers and give rise to stimulation of the visual

system, causing the symptoms of entoptic phenomena [16]. One of the most common in the visual snow syndrome is floaters, the perception of which is defined as myodesopsia. Floaters are bits and strands of vitreous that float in the vitreous humor itself causing stimulation of the retina; they can be seen best when viewing a white or blue background. The key feature of floaters is that they move slowly with changes in gaze and that they are of variable diameter and brightness.

Some individuals have a keen enough power of observation to see their own white blood cells flowing within the retinal microvasculature, and can perceive them as little cells or dots darting around in a squiggly path, especially when looking at the blue sky. This phenomenon can be brought out by using a blue field entoptoscope and is defined accordingly as the blue field entoptic – or Scheerer's – phenomenon [30]. It is present in visual snow in up to 80% of study participants.

Another important entoptic phenomena present in visual snow, which is observed in other eye diseases, are spontaneous flashes of light, also known as photopsias. This manifestation, especially when associated with a sudden increase in floaters and when more apparent in the dark, can be the symptom of retinal or vitreal detachment [31]. If accompanied by glares, shimmering around objects, visual loss, and night blindness, photopsias can also be caused by both retinal degeneration and paraneoplastic retinal degeneration – so-called cancer-associated retinopathy or melanoma-associated retinopathy syndromes. The keys to not missing the above diagnoses are a good ophthalmologic examination – including acuity, visual fields when appropriate, and a dilated fundus examination; an electroretinogram is useful when the diagnosis remains unclear [32].

Photophobia is very common in migraine, and it is common in other ocular pathologies; nearly two-thirds of individuals with visual snow report light sensitivity as well [1²²]. The key characteristic of photophobia is the avoidance of light, which is reported by individuals as being either too bright (photoc hypersensitivity) or painful (photoc allodynia) [33]. It is indeed difficult to assess how much of the photophobic component of visual snow patients is actually because of the migraine comorbidity in these study participants.

Finally, about two-thirds of individuals with visual snow report nyctalopia. This symptom, defined as a difficulty seeing at night or in the dark, can be a sign of retinal degeneration or low vitamin A. Interestingly, as with all other additional visual symptoms, nyctalopia is present in the visual snow syndrome even in study participants with

completely normal retinal examinations. Some patients attribute their reduced night vision to an increased combination of palinopsia and entoptic phenomena in low light, whereas others simply describe the static as being more noticeable with the absence of other light stimuli, pointing to a possible dysregulation in the cortical processing of incoming sensory stimulation.

CONCLUSION

The proposal of a case definition for visual snow has been reasonably received, and this is a crucial step to characterize the disorder clinically in large numbers of study participants and to understand its pathophysiological mechanisms. The careful collection of clinical material, and better understanding of the condition, is essential if progress is to be made toward developing broadly useful therapeutic approaches. Furthermore, it is crucial that the disease be recognized by physicians, particularly by neurologists and ophthalmologists, who have a high chance of encountering it in their clinical practice. This alone would certainly reduce the stress that most patients deal with in the lengthy quest of reaching a clear diagnosis for their condition.

Acknowledgements

The authors would like to thank the more than 1000 patients who have contacted the study team in recent years to take part in research and share their experiences. It is thanks to their active participation that knowledge on this condition is being gradually achieved. We would particularly like to thank the Eye on Vision Foundation, which is currently active in crowdfunding campaigns to support the research being conducted on visual snow syndrome.

Financial support and sponsorship

Work on visual snow conducted by F.P., C.S., and P.J.G. has been funded by Eye on Vision Foundation, Sierra Domb, the German Research Foundation, and the German Migraine and Headache Society.

K.D. is supported in part by an Unrestricted Grant from Research to Prevent Blindness, Inc., New York, NY, to the Department of Ophthalmology and Visual Sciences, University of Utah.

P.J.G. reports grants and personal fees from Allergan, Amgen, and Eli-Lilly and Company; and personal fees from Akita Biomedical, Alder Biopharmaceuticals, Avanir Pharma, Cipla Ltd, Dr Reddy's Laboratories, eNeura, Electrocore LLC, Novartis, Pfizer Inc, Quest Diagnostics, Scion, Teva Pharmaceuticals, Trigemina Inc., Scion; and personal fees from MedicoLegal work, Journal Watch, Up-to-Date, Massachusetts Medical

Society, Oxford University Press; and in addition, Dr Goadsby has a patent Magnetic stimulation for headache assigned to eNeura.

Conflicts of interest

There are no conflicts of interest.

REFERENCES AND RECOMMENDED READING

Papers of particular interest, published within the annual period of review, have been highlighted as:

- of special interest
- of outstanding interest

1. Schankin CJ, Maniyar FH, Digre KB, *et al.* 'Visual snow': a disorder distinct from persistent migraine aura. *Brain* 2014; 137:1419–1428. The study represents the first systematic characterization of visual snow, following a three-step approach. It further allowed to define the clinical criteria for the visual snow syndrome.
 2. Puledda F, Schankin C, Goadsby PJ. Clinical characterization of visual snow. *Cephalalgia* 2016; 36:127.
 3. Liu GT, Schatz NJ, Galetta SL, *et al.* Persistent positive visual phenomena in migraine. *Neurology* 1995; 45:664–668.
 4. Jager HR, Giffin NJ, Goadsby PJ. Diffusion and perfusion-weighted MR imaging in persistent migrainous visual disturbances. *Cephalalgia* 2005; 25:323–332.
 5. Wang YF, Fuh JL, Chen WT, Wang SJ. The visual aura rating scale as an outcome predictor for persistent visual aura without infarction. *Cephalalgia* 2008; 28:1298–1304.
 6. Chen WT, Lin YY, Fuh JL, *et al.* Sustained visual cortex hyperexcitability in migraine with persistent visual aura. *Brain* 2011; 134:2387–2395.
 7. Simpson JC, Goadsby PJ, Prabhakar P. Positive persistent visual symptoms (visual snow) presenting as a migraine variant in a 12-year-old girl. *Pediatric neurology* 2013; 49:361–363.
- In this study, the first clinical description of visual snow as a distinct phenomenon is made in a pediatric patient.
8. Schankin CJ, Maniyar FH, Sprenger T, *et al.* The relation between migraine, typical migraine aura and 'visual snow'. *Headache* 2014; 54:957–966. The study describes the first neuroimaging study performed in visual snow patients, which showed a hypermetabolism of the lingual gyrus, a key area of the visual cortex.
 9. Bessero AC, Plant GT. Should 'visual snow' and persistence of after-images be recognised as a new visual syndrome? *J Neurol Neurosurg Psychiatry* 2014; 85:1057–1058.
 10. Unal-Cevik I, Yildiz FG. Visual snow in migraine with aura: further characterization by brain imaging, electrophysiology, and treatment: case report. *Headache* 2015; 55:1436–1441.
 11. Lauschke JL, Plant GT, Fraser CL. Visual snow: a thalamocortical dysrhythmia of the visual pathway? *J Clin Neurosci* 2016; 28:123–127.
 12. McKendrick AM, Chan YM, Tien M, *et al.* Behavioral measures of cortical hyperexcitability assessed in people who experience visual snow. *Neurology* 2017; 88:1243–1249.
 13. Schankin CJ, Goadsby PJ. Visual snow: persistent positive visual phenomenon distinct from migraine aura. *Curr Pain Headache Rep* 2015; 19:23.
 14. Headache Classification Committee of the International Headache Society (IHS). The International Classification of Headache Disorders, 3rd edition (beta version). *Cephalalgia* 2013; 33:629–808.
 15. Critchley M. Types of visual perseveration: 'palinopsia' and 'illusory visual spread'. *Brain* 1951; 74:267–299.
 16. Tyler CW. Some new entoptic phenomena. *Vision Res* 1978; 18:1633–1639.
 17. Denuelle M, Bouloche N, Payoux P, *et al.* A PET study of photophobia during spontaneous migraine attacks. *Neurology* 2011; 76:213–218.
 18. Chong CD, Starling AJ, Schwedt TJ. Interictal photosensitivity associates with altered brain structure in patients with episodic migraine. *Cephalalgia* 2016; 36:526–533.
 19. Brodmann K. Vergleichende lokalizationslehre der großhirnrinde: in ihren prinzipien dargestellt auf grund des zellenbaues. Leipzig: Johann Ambrosius Barth 1909.
 20. Hadjikhani N, Sanchez Del Rio M, Wu O, *et al.* Mechanisms of migraine aura revealed by functional MRI in human visual cortex. *Proc Natl Acad Sci U S A* 2001; 98:4687–4692.
 21. Schankin CJ, Viana M, Goadsby PJ. Persistent and repetitive visual disturbances in migraine: a review. *Headache* 2017; 57:1–16.
 22. Schoenen J, Wang W, Albert A, Delwaide PJ. Potentiation instead of habituation characterizes visual evoked potentials in migraine patients between attacks. *Eur J Neurol* 1995; 2:115–122.

23. Puledda F, Schankin C, Goadsby PJ. Treatment effect in visual snow. *Cephalalgia* 2016; 36:127.
24. Kinsbourne M, Warrington EK. A study of visual perseveration. *J Neurol Neurosurg Psychiatry* 1963; 26:468–475.
25. Bender MB, Feldman M, Sobin AJ. Palinopsia. *Brain* 1968; 91:321–338.
26. Evans RW. Reversible palinopsia and the Alice in Wonderland syndrome associated with topiramate use in migraineurs. *Headache* 2006; 46: 815–818.
27. Vogt PH, Barr G, Maitland CG. Palinopsia: side effect of topiramate and acetazolamide. *J Neuroophthalmol* 2016; 36:347–348.
28. Gersztenkorn D, Lee AG. Palinopsia revamped: a systematic review of the literature. *Surv Ophthalmol* 2015; 60:1–35.
29. Belcastro V, Cupini LM, Corbelli I, *et al.* Palinopsia in patients with migraine: a case-control study. *Cephalalgia* 2011; 31:999–1004.
30. von Helmholtz H. Verschiedene subjective Erscheinungen. In: *Handbuch der physiologischen optik*. 2nd ed. Hamburg und Leipzig: Verlag von Leopold Voss; 1896. p. 572.
31. Brown GC, Brown MM, Fischer DH. Photopsias: a key to diagnosis. *Ophthalmology* 2015; 122:2084–2094.
32. Braithwaite T, Holder GE, Lee RW, *et al.* Diagnostic features of the autoimmune retinopathies. *Autoimmun Rev* 2014; 13:534–538.
33. Maniyar FH, Sprenger T, Schankin C, Goadsby PJ. Photic hypersensitivity in the premonitory phase of migraine: a positron emission tomography study. *Eur J Neurol* 2014; 21:1178–1183.